

In vitro effects of estradiol on pituitary GH-immunoreactive cells

J. Carretero, M. Rubio, F. Sánchez, J. Pereña, F.I. Estévez, G. Vázquez, R.M. Pérez and R. Vázquez

Department of Human Anatomy and Histology, School of Medicine, University of Salamanca, Salamanca, Spain

Summary. In order to determine whether estradiol modulates the proliferation and activity of somatotrophic cells in vitro, a study of GH-immunoreactive cells was carried out in pituitary monolayer cultures obtained from male adult rats treated with 10^{-6} M estradiol for 3 hours. Cellular activity was evaluated in a morphometric study of GH-immunoreactive cells. The proliferation rate was determined by double immunostaining for GH and PCNA (proliferating cellular nuclear antigen). The results were compared to those obtained from control dishes. Estradiol was seen to increase the cellular ($p < 0.05$), nuclear ($p < 0.01$) and cytoplasmic areas ($p < 0.05$). Estradiol decreased the percentage of proliferating GH-immunoreactive cells ($p < 0.05$) and the numerical density of somatotrophs ($p < 0.05$) when all cells present in the dishes were considered. However, when only GH-immunoreactive cells were considered, estradiol increased the proliferation rate of these cells ($p < 0.05$). Overall, our results suggest that, in vitro, estradiol stimulates the cellular activity and proliferation of GH-immunoreactive cells in the rat.

Key words: Estradiol, Pituitary, Immunohistochemistry, GH

Introduction

In the adult rat, the patterns of GH secretion have gender-related differences (Saunders et al., 1976; Eden, 1979; Tannenbaum and Ling, 1984; Plotsky and Vale, 1985; Jansson et al., 1985; Millard et al., 1986; Hertz et al., 1989). Castration modifies the body weight of the adult rat (Carretero et al., 1993) and, in vivo, estrogens stimulate the secretion of GH (Moll et al., 1986; Simard et al., 1986, 1988; Papas et al., 1988) and inhibit the release of somatostatin (Mobbs et al., 1985; Eriksson et al., 1988).

These modulations exerted by estradiol may explain

why plasma GH levels are decreased after ovariectomy (Mobbs et al., 1985; Eriksson et al., 1988) and why the number and size of pituitary GH-immunoreactive cells are increased (Gross, 1980; Carretero et al., 1990), together with an increase in the cytoplasmic immunoreaction. In vivo, we have previously demonstrated that treatment with estradiol induces an increase in GH levels accompanied by decreases in the cellular and cytoplasmic areas of GH-immunoreactive cells and a decrease in the cytoplasmic immunoreaction (Carretero et al., 1992a).

In order to determine the direct effects of estradiol on pituitary GH-immunoreactive cells, an in vitro immunocytochemical study was carried out, determining cellular activity by morphometric analysis of these cells. The study was completed with the determination of the in vitro proliferation rate of GH-immunoreactive cells by double immunostaining for PCNA and GH.

Materials and methods

Pituitary cultures

Following anaesthesia with isoflurane, male Wistar rats (175-200 g) were killed by decapitation and the anterior pituitary glands were removed and washed in Earle's balanced salt solution. Enzymatic dispersion was carried out by incubation for 15 minutes at 37 °C in Hank's solution to which 0.15% $MgCl_2$, 0.1% papain, 0.01% DNase and 0.1% of neutral protease had been added. Mechanical dispersion was achieved by passing the pituitary glands through Pasteur pipettes and 20 to 22 gauge needles. After centrifugation, the supernatant was removed and the cells were resuspended in an appropriate volume of Dulbecco's modified Eagle's medium, supplemented with 10% calf serum, 2.5% fetal calf serum, 2% L-glutamine, 1000 IU/ml of penicillin and 1000 IU/ml of streptomycin (Carretero et al., 1995a). Cells were seeded on culture dishes (30x15 mm) at a final concentration of 5×10^5 cells/dish and incubated at 37 °C in a 5% CO_2 /95% air atmosphere for 7 days. On the 4th day of incubation the medium was replaced by fresh medium. On the 7th day of incubation, the medium

Effect of estradiol on GH-cells

was replaced by fresh medium in the control dishes and fresh medium plus 17- β -estradiol (100nM) in the treated dishes. Previously, 17 β -estradiol was diluted in ethanol, the final concentration of ethanol in the treated and control dishes being 0.0027%. After 3 hours of incubation, the culture medium was removed, the dishes were carefully washed with Dulbecco's sterile PBS, and the cells were fixed in Bouin solution for 1 hour, followed by careful rinsing in PBS. In order to verify the results obtained, two pituitary cultures were made up under identical experimental conditions (40 dishes per culture were used and divided into 4 study groups: 10 control dishes were stained for GH, 10 control dishes were stained for GH and PCNA, 10 estradiol-treated dishes were stained for GH, and 10 estradiol-treated dishes were stained for GH and PCNA).

Immunocytochemistry

To study GH-immunoreactive cells the PAP method was employed, using anti-GH rabbit serum (Dako, diluted 1:1000), swine anti-rabbit serum (Dako, diluted 1:1000) and rabbit-PAP complex (Dako, diluted 1:100). Endogenous peroxidase was blocked with H₂O₂ in methanol and non-specific reactions of the secondary antibody by incubation in normal swine serum (Dako, diluted 1:30). For the washes and dilutions of the sera, tris buffer (0.05M, pH 7.4) containing 0.8% NaCl was used. The reaction was developed in freshly prepared 3,3'-diaminobenzidine (DAB) (Sigma, 0.025% in TRIS buffer containing 0.03% H₂O₂). To study PCNA-positive cells and to determine the PCNA-GH labelling index, a double labelling immunohistochemical method for PCNA and GH was applied. Endogenous peroxidase was blocked with H₂O₂ in methanol, and non-specific reactions of the secondary antibody by incubation in normal goat serum (Dako, diluted 1:30). Cultures were incubated overnight at 4 °C with mouse PC10 (PCNA) mAb (Dako, lot. 121 diluted 1:3000 in TBS). Biotinylated goat anti-mouse IgG (Dako, lot. 061 diluted 1:100) and Avidin-Biotinylated horseradish peroxidase complex (ABC kit, Dako lot. 081 diluted 1:100) were successively applied at room temperature for 40 min and 30 min, respectively. The reaction was developed in freshly prepared DAB (0.025% in TRIS buffer containing 0.03% H₂O₂). Following PCNA immunolabelling, the peroxidase-antiperoxidase (PAP) reaction was performed for the detection of GH, using rabbit antisera against GH in a way similar to that described above for single immunolabeling, but the second immunoreaction was developed in 4-chloro-1-naphthol (1.7x10⁻³M in 3% absolute ethanol and TRIS-buffer containing 0.3% H₂O₂). Following absorption of the primary anti-GH serum with GH, the immunoreaction was abolished and after replacement of the anti-GH serum by normal rabbit serum in the double immunostaining, only PCNA nuclear expression was found.

Morphometry

Using an MIP-2 (IMCO 10) image analyzer, the cellular, nuclear and cytoplasmic areas of 50 GH immunoreactive cells per culture dish (500 cells per group and culture) were calculated from single immunolabelled cells.

Quantification of PCNA, GH and PCNA-GH immunoreactive cells

Four thousand cells per dish were evaluated using an Axiophot Zeiss microscope equipped with an ocular grid at a final magnification of x 400. The cells were randomly selected from different areas of the dishes. Dishes with a strong agglomeration of overlapping cells were rejected and only non-overlapping cells were considered. The following parameters were determined: 1) Total number of cells, 2) PCNA-positive cells, 3) GH-positive cells and 4) PCNA- and GH-positive cells; 2, 3 and 4 were calculated as percentages of the total number of cells per field; the percentages of PCNA- and GH-immunoreactive cells from the GH-positive cells were calculated.

Statistical analysis

Two pituitary cultures were made up under similar experimental conditions in order to verify the reproducibility of the results (assay error was always less than 1.5%). For each parameter evaluated, the values obtained were processed statistically. Data from individual experiments were subjected to ANOVA followed by the Scheffé-F test for multiple comparisons, accepting p<0.05 as significant. Results are expressed as arithmetical means \pm SEM.

Results

Morphological findings

Two different cells immunoreactive to GH were found in the control (untreated) dishes: strong and weakly stained cells. The strong GH-immunoreactive cells had oval, excentric nuclei and their cytoplasm appeared homogeneously stained (Fig. 1). The weakly GH-immunoreactive cells showed round or irregular nuclei and their cytoplasm displayed a weak reaction (Fig. 2). After treatment with estradiol, the strong GH-immunoreactive cells showed an irregular deposit of chromogen in their cytoplasm (Fig. 3) and the weakly stained cells showed excentric nuclei, the cytoplasm appearing with a granular deposit of chromogen.

Morphometric findings

In vitro, the cellular area of GH-immunoreactive cells from the untreated dishes was 75.91 \pm 5.31 μ m²; the nuclei occupied 39.19% of this surface, and the

Effect of estradiol on GH-cells

cytoplasm the other 60.81% (see Table 1). Treatment with estradiol induced significant increases in the cellular ($p<0.01$), cytoplasmic ($p<0.05$) and nuclear ($p<0.01$) areas of the GH-immunoreactive cells.

Proliferation rates (Table 1)

The *in vitro* percentage of proliferating pituitary cells in untreated dishes was $56.09\pm3.43\%$. After treatment with estradiol, these percentages increased

Table 1. Morphometric values (μm^2) and labelling index for GH (%GH-ir cells) and for GH and PCNA (%GH- and PCNA-ir cells) and percentage of proliferating GH-immunoreactive cells (%GH- and PCNA-ir cells/GH-ir cells) found in control and estradiol-treated dishes.

	CONTROL	ESTRADIOL
Cellular area	75.91 \pm 5.31	98.43 \pm 5.46*
Cytoplasmic area	46.16 \pm 3.39	57.84 \pm 3.72*
Nuclear area	29.75 \pm 1.47	40.59 \pm 1.97**
%GH-ir cells	19.10 \pm 0.84	11.61 \pm 0.58*
%GH- and PCNA-ir cells	10.85 \pm 0.93	7.25 \pm 0.57*
%GH- and PCNA-ir cells/GH-ir cells	56.21 \pm 3.30	62.45 \pm 3.51*

*: $p<0.05$ with respect to controls dishes; **: $p<0.01$ with respect to control dishes.

significantly ($p<0.05$).

The percentage of GH-immunoreactive cells was calculated to be $19.10\pm0.84\%$ of all the cells present in the untreated dishes and decreased significantly ($p<0.01$) after treatment with estradiol.

The percentages of GH- and PCNA-immunoreactive cells after treatment with estradiol were modified in a different way when the percentages were calculated considering all cells per dish than when only GH-immunoreactive cells were considered.

In the first case, the PCNA- and GH-immunoreactive cells comprised $10.85\pm0.93\%$ of the cells present in the untreated dishes, and only $7.25\pm0.57\%$ of the cells present in the estradiol-treated dishes were PCNA- and GH-immunoreactive cells ($p<0.05$).

When only GH-immunoreactive cells were considered $56.21\pm3.30\%$ of the GH-immunoreactive cells were reactive to GH and PCNA jointly in the untreated dishes, and estradiol induced a significant increase in GH-immunoreactive proliferating cells ($p<0.05$).

Discussion

Gonadal steroids modulate the secretion of GH

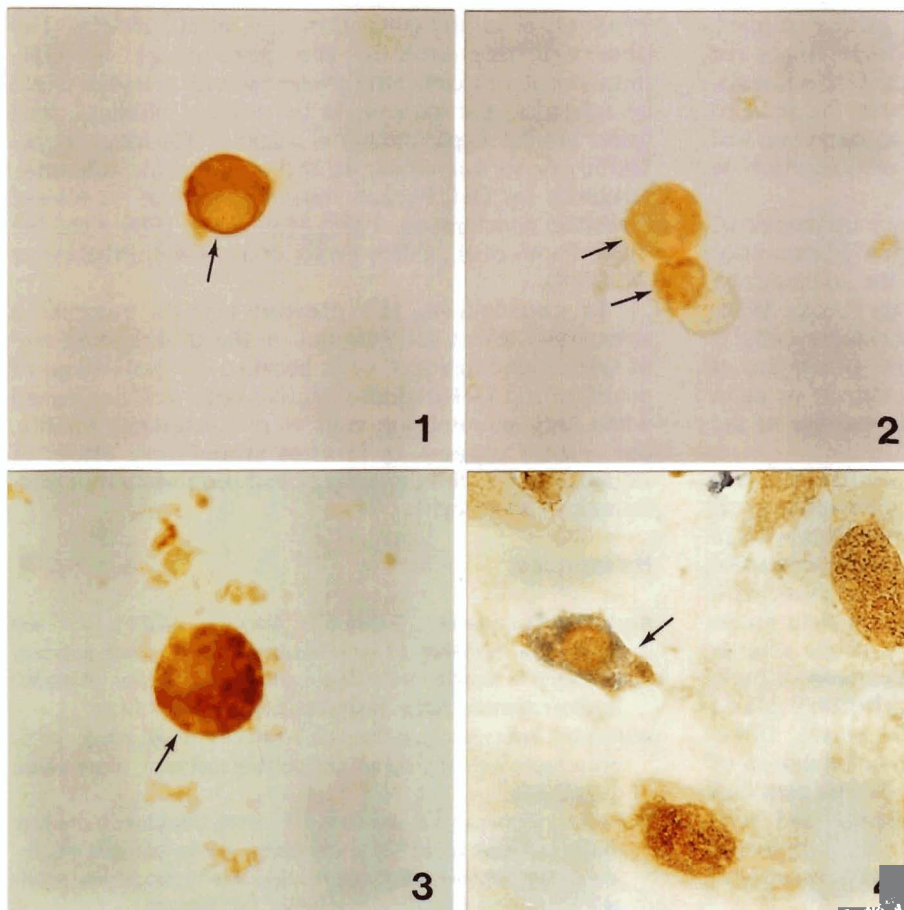


Fig. 1. Strong GH-immunoreactive cells (arrow) from a control dish. x 1,000

Fig. 2. Weakly-stained GH-immunoreactive cells (arrows) from a control dish. x 1,000

Fig. 3. Strong GH-immunoreactive cell (arrow) with an irregular deposit of chromogen in its cytoplasm after treatment with estradiol. x 1,000

Fig. 4. Proliferating GH-immunoreactive cell (arrow) after treatment with estradiol. The nucleus shows immunoreaction for PCNA (brown) and the cytoplasm appears irregularly reactive for GH (blue). x 625

(Eriksson and Janson, 1985; Martin et al., 1985; Wehrenberg et al., 1985; Millard et al., 1986; Moll et al., 1986; Quabbe, 1986; Smals et al., 1986; Akira et al., 1988; Breier et al., 1988; Eriksson et al., 1988; Papas et al., 1988) and there is evidence for a hypothalamic modulation (Eriksson and Jansson, 1985; Simard et al., 1986, 1988; Silverman et al., 1988) that would be partially responsible for the gender differences observed in the pattern of GH release in the adult rat and described by different authors (Saunders et al., 1976; Eden, 1979; Jansson et al., 1985; Martin et al., 1985; Millard et al., 1986).

When hypothalamic control is abolished, GH release is similar in both male and female rats; however, morphometric differences in GH-immunoreactive cells, from males to females, have previously been observed in our laboratory (Carretero et al., 1992b), suggesting non-central effects of gonadal steroids on the activity of these cells.

In a previous study we analyzed the changes observed in the cellular and nuclear sizes of the lactotroph cells which were related to the changes in the proliferation rates (Carretero et al., 1995a). The study of the effects of estradiol on GH-immunoreactive cells was carried out after 7 days of evolution of the cultures, because in this study we observed that after 7 days, but not after 3 days, the percentages of secretory cells were similar to the percentages observed in *in vivo* studies. This is the reason why different culture times for evaluation of the effects of estradiol on GH-immunoreactive cells were not assayed. Moreover, the *in vitro* results of the present study demonstrate an important and direct effect of estradiol on size and proliferation of pituitary GH-immunoreactive cells.

Evidence exists which points to an influence of gonadal steroids in the morphology of GH-immunoreactive cells. *In vivo*, it is known that the somatotroph cells of males are larger than in female rats (Gross, 1980; Schulte et al., 1980) and that after ovariectomy cellular immunoreactivity (Gross, 1980) and size (Carretero et al., 1990) are increased. Moreover, treatment of male rats with estradiol induces a decrease in the size of the cells (Carretero et al., 1992a).

In vitro, the present results demonstrate the influence of *in vitro* estradiol administration in the morphological characteristics of the cells. However, differences with *in vivo* results are evident: morphometrically, estradiol induces hyperplasia of somatotroph cells *in vitro*, with increases in the cellular, cytoplasmic and nuclear areas. These differences could be related to other effects exerted by estradiol *in vivo*, such as a decrease in tonic somatostatinergic inhibition of the pituitary gland induced by estradiol (Chowed-Breed et al., 1989; Gabriel et al., 1989; Zeitler et al., 1990) or inhibition of the hepatic release of IGF-1, induced *in vivo* by estradiol (Dawson and Hughes et al., 1986; Frohlander and Von-Schoultz, 1988). The morphometric findings reported here suggest that, *in vitro*, estradiol induces hyperactivity in GH-immunoreactive cells.

In vivo, variations in the numerical density and proliferation rate (labelling index for Bromodeoxyuridine) of GH-immunoreactive cells related to the sexual cycle in adult female rats have been reported to be maximal in the proestrus and minimal in the metaestrus phases (Oishi et al., 1993). However, because our study was an *in vitro* analysis and the method for determining the proliferation rate was different, it is not possible to compare our results with those of Oishi et al.

Our study is the first analysis of the *in vitro* proliferation rate of GH-immunoreactive cells after estradiol treatment by analyzing the immunocytochemical expression of PCNA. *In vivo*, Oishi et al. (1993) demonstrated that PCNA is more sensitive than BrDU for the determination of the proliferation rate of pituitary cells in the adult rat and, in a previous study (Carretero et al., 1995b), we have demonstrated that PCNA is a good marker for detecting pituitary proliferating cells *in vitro*.

With the method used, the present study demonstrates that estradiol increases the total proliferation rate of pituitary monolayer cultures, probably because it stimulates the cellular proliferation of different types of cells, such as lactotroph or VIPergic cells, and increases the numerical density of these cells (Allason et al., 1969; Zambrano and Deis, 1970; Lieberman et al., 1982; Sakuma et al., 1984; Perez et al., 1986; Drewett et al., 1993; Oishi et al., 1993; Carretero et al., 1995b). The observed decrease in the percentage of GH-immunoreactive cells after treatment with estradiol could be related to the increase in those other pituitary cells under similar experimental conditions (Carretero et al., 1995b) or to a decrease in the cytoplasmic immunoreactivity for GH, because estradiol induces its release (Eriksson and Jansson, 1985; Moll et al., 1986; Quabbe, 1986; Papas et al., 1988; Breier et al., 1988; Eriksson et al., 1988).

In conclusion, the present results suggest a stimulatory effect for estradiol on the proliferation rate of GH-immunoreactive cells because the percentage of proliferating GH-immunoreactive cells was increased when only somatotroph cells were considered. Finally, our results suggest an *in vitro* stimulatory effect of estradiol on the cellular activity and proliferation of GH-immunoreactive cells.

References

- Akira S., Wakabayashi I., Sugihara H., Minami S., Takahashi F. and Moyoyama A. (1988). Effect of testosterone on growth hormone secretion in female rats during a continuous infusion of growth hormone releasing factor. *Neuroendocrinology* 47, 116-124.
- Allason M., Foster C.L. and Cameron E. (1969). Mitotic activity in the adenohipophysis of pregnant and lactating rabbits. *J. Reprod. Fert.* 19, 121-131.
- Breier B.H., Gluckman P.D. and Bass J.J. (1988). Influence of nutritional status and oestradiol-17 beta on plasma growth hormone, insulin-like growth factors-I and II and the response to exogenous growth hormone in young steers. *J. Endocrinol.* 118, 243-250.

Effect of estradiol on GH-cells

- Carretero J., Sánchez F., Montero M., Blanco E., Riesco J.M., Carbajo E., González R. and Vázquez R. (1990). Morphological and functional study of the GH-immunoreactive adenohypophyseal cells in ovariectomized rats. *Histochem. J.* 22, 683-687.
- Carretero J., Sánchez F., González R., Montero M., Juanes J.A., Riesco J.M. and Vázquez R. (1992a). Morphometric analysis of GH-immunoreactive cells after GH release induced by treatment with oestrogen in adult male rats. *Acta Histochem.* 93, 271-276.
- Carretero J., Sánchez F., Rubio M., Juanes J.A., Blanco E., González R., Riesco J.M. and Vázquez R. (1992b). Morphometric changes in GH-immunoreactive adenohypophyseal cells induced by intraventricular administration of colchicine to adult rats. *Histol. Histopathol.* 7, 673-677.
- Carretero J., González R., Rubio M., Sánchez F., Angoso M., Riesco J.M. and Vázquez R. (1993). Variations of the corporal growth following experimental manipulation of the gonadal environment in adult rats. *An. Anat.* 39, 3-9.
- Carretero J., Rubio M., Navarro N., Prieto P., Vázquez R.J., Sánchez F. and Vázquez R. (1995a). In vitro modifications in the proliferation rate of prolactin cells are accompanied by nuclear morphometric variations. *Histol. Histopathol.* 10, 135-139.
- Carretero J., Rubio M., Sánchez F., Vázquez R.J., Santos M., Blanco J. and Vázquez R. (1995b). In vitro morphometric and proliferative variations in VIP-immunoreactive pituitary cells induced by estradiol. *Neuroendocrinology* 62, 277-282.
- Chowd-Breed J.A., Steiner R.A. and Clifton D.K. (1989). Sexual dimorphism and testosterone-dependent regulation of somatostatin gene expression in the periventricular nucleus of the rat brain. *Endocrinology* 125, 357-362.
- Dawson-Hughes B., Stern D., Goldman J. and Reichlin S. (1986). Regulation of growth hormone and somatomedin-C secretion in postmenopausal women: effect of physiological estrogen replacement. *J. Clin. Endocrinol. Metab.* 63, 424-432.
- Drewett N., Jacobi J.M., Willgoss D. and Lloyd H.M. (1993). Apoptosis in the anterior pituitary gland of the rat: studies with estrogen and bromocriptine. *Neuroendocrinology* 57, 89-95.
- Eden S. (1979). Age and sex related differences in episodic growth hormone secretion in the rat. *Endocrinology* 105, 555-560.
- Eriksson E. and Jansson J.O. (1985). Estradiol increases growth hormone secretion in rats exposed to swimming stress or reserpine treatment. *Life Sci.* 37, 1241-1248.
- Eriksson E., Modigh K. and Jansson J.O. (1988). Effects of sex steroids on growth hormone responses to clonidine and GHRH in reserpine pretreated rats. *J. Neural Trans.* 71, 99-113.
- Frohlander N. and Von-Schoultz B. (1988). Growth hormone and somatomedin-C during post-menopausal replacement therapy with oestrogen alone and in combination with an antioestrogen. *Maturitas* 9, 297-302.
- Gabriel S.M., Millard W.J., Koenig J.J., Badger T.M., Russel W.E., Maitter D.M. and Martin J.B. (1989). Sexual and developmental differences in peptides regulating growth hormone secretion in the rat. *Neuroendocrinology* 50, 299-307.
- Gross D.S. (1980). Role of somatostatin in the modulation of hypophysial growth hormone production by gonadal steroids. *Am. J. Anat.* 158, 507-519.
- Hertz P., Silverman M., Even L. and Hochberg M. (1989). Effects of sex steroids on the response of cultured rat pituitary cells to growth hormone-releasing hormone and somatostatin. *Endocrinology* 125, 581-585.
- Jansson J.O., Ekberg S., Isaksson O.G.P., Mode A. and Gustafsson J.A. (1985). Imprinting of growth hormone secretion, body growth and hepatic steroid metabolism by neonatal testosterone. *Endocrinology* 117, 1881-1889.
- Lieberman M.E., Maurer R.A., Claude P. and Gorski J. (1982). Prolactin synthesis in primary cultures of pituitary cells. Regulation by estradiol. *Mol. Cell. Endocrinol.* 25, 277-294.
- Martin J.B., Fukata J., Millard W., McCormick S. and Badger T. (1985). Pituitary and extrapituitary actions of GRF and somatostatin. *Folia Endocrinol. Jpn.* 61, 231-232.
- Millard W.J., Politch J.A., Martin J.B. and Fox T.O. (1986). Growth hormone-secretory patterns in androgen-resistant (testicular feminized) rats. *Endocrinology* 119, 2655-2660.
- Mobbs C.V., Cheyney D., Sinha Y.N. and Finch C.E. (1985). Age-correlated and ovary-dependent changes in relationship between plasma estradiol and luteinizing hormone, prolactin and growth hormone in female C57BL/6J mice. *Endocrinology* 116, 813-820.
- Moll G.W. Jr., Rosenfield R.L. and Fang V.S. (1986). Administration of low-dose estrogen rapidly and directly stimulates growth hormone production. *Am. J. Dis. Child* 140, 124-127.
- Oishi Y., Okuda M., Takahashi H., Fujii T. and Morii S. (1993). Cellular proliferation in the anterior pituitary gland of normal adult rats: influences of sex, estrous cycle, and circadian change. *Anat. Rec.* 235, 111-120.
- Papas S., Shin S.H. and Obonsawin M.C. (1988). Bovine neurophysin II stimulates growth hormone release in the estradiol-primed male rat. *Neuroendocrinology* 47, 154-158.
- Perez R.L., Machiavelli G.A., Romano M.I. and Burdman J.A. (1986). Prolactin release, oestrogens and proliferation of prolactin-secreting cells in the anterior pituitary gland of adult male rats. *J. Endocrinol.* 108, 399-403.
- Plotzky P.M. and Vale W. (1985). Patterns of growth hormone-releasing factor and somatostatin secretion into the hypophysial portal circulation of the rat. *Science* 230, 461-463.
- Quabbe H.J. (1986). Growth hormone. In: *Neuroendocrinology*. Lightman S.L. and Everitt B.J. (eds). Blackwell Scientific Publications, Oxford, pp 409-449.
- Sakuma S., Shirasawa N. and Yoshimura F. (1984). A histometrical study of immunohistochemically identified mitotic adenohypophyseal cells in immature and mature castrated rats. *J. Endocrinol.* 100, 323-328.
- Saunders A., Terry L.C., Audet J., Brazeau P. and Marti J.B. (1976). Dynamic studies of growth hormone prolactin secretion in the female rat. *Neuroendocrinology* 21, 193-203.
- Schulte S.A., Seal U.S., Plotka E.D., Verme L.J., Ozoga J.J. and Parsons J.A. (1980). Seasonal changes in prolactin and growth hormone cells in the hypophyses of white-tailed (*Odocoileus virginianus borealis*) studies by light microscopic immunocytochemistry and radioimmunoassay. *Am. J. Anat.* 159, 369-377.
- Silverman B.L., Kaplan S.L., Grumbach M.M. and Miller W.L. (1988). Hormonal regulation of growth hormone secretion and messenger ribonucleic acid accumulation in cultured bovine pituitary cells. *Endocrinology* 122, 1236-1241.
- Simard J., Hubert J.F., Hosseinzadeh T. and Labrie F. (1986). Stimulation of growth hormone release and synthesis by estrogens in rat anterior pituitary cells in culture. *Endocrinology* 119, 2004-2011.
- Simard J., Vincent A., Duchesne R. and Labrie F. (1988). Full oestrogenic activity of C19-delta 5 adrenal steroids in rat pituitary

Effect of estradiol on GH-cells

- lactotrophs and somatotrophs. *Mol. Cell Endocrinol.* 55, 233-242.
- Smals A.E., Pieters G.F., Smals A.G., Benraad T.J., Van-Laarhoven J. and Kloppenborg P.W. (1986). Sex difference in human growth hormone (GH) response to intravenous human pancreatic GH-releasing hormone administration in young adults. *J. Clin. Endocrinol. Metab.* 62, 336-341.
- Tannenbaum G.S. and Ling N. (1984). The interrelationship of growth hormone (GH)-releasing factor and somatostatin in generation of the ultradian rhythm of GH secretion. *Endocrinology* 115, 1952-1957.
- Wehrenberg W.B., Baird A., Ying S.Y. and Ling N. (1985). The effects of testosterone and estrogen on the pituitary growth hormone response to growth hormone releasing factor. *Biol. Reprod.* 32, 369-375.
- Zambrano D. and Deis R.P. (1970). The adenohypophysis of female rats after hypothalamic oestradiol implants: an electron microscopic study. *J. Endocrinol.* 47, 101-110.
- Zeitler P., Argente J., Chowen-Breed J.A., Clifton D.K. and Steiner R.A. (1990). Growth hormone-releasing hormone messenger ribonucleic acid is increased by testosterone. *Endocrinology* 127, 1362-1368.

Accepted December 13, 1996